



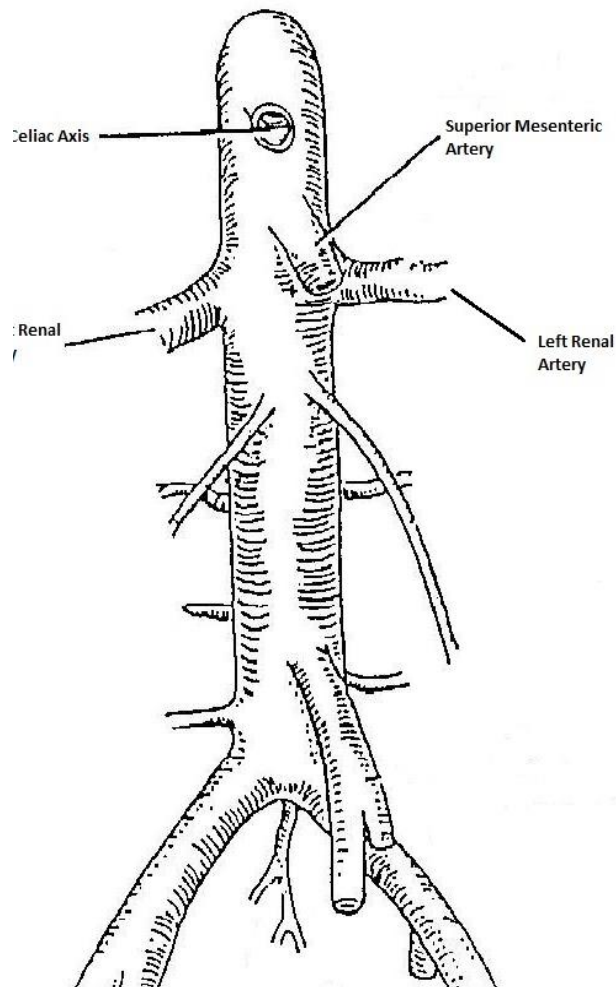
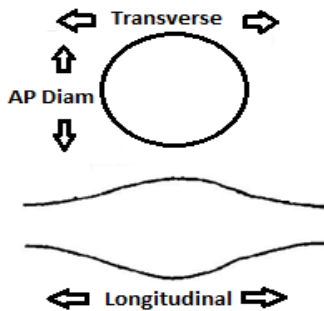
## CARDIORISK AAA SCREENING

Patient Name: Shellhorn, Elaine Date: 6/10/2020

DOB: 9/2/1939 Sex: F

Referring Provider: Robert Leff, MD

Vascular Technician: Sandra Kuljis



### Aorta Prox

1.6 cm Trans X 1.4 cm AP

### Aorta Mid

2.0 cm Trans X 1.7 cm AP

### Aorta Distal

1.4 cm Trans X 1.5 cm AP

Comments: No Abdominal Aortic Aneurysm was identified in the submitted images. There was a small amount of calcified plaque identified in the Abdominal Aorta. There is a suggestion of soft plaque visualized in the Abdominal Aorta.



