



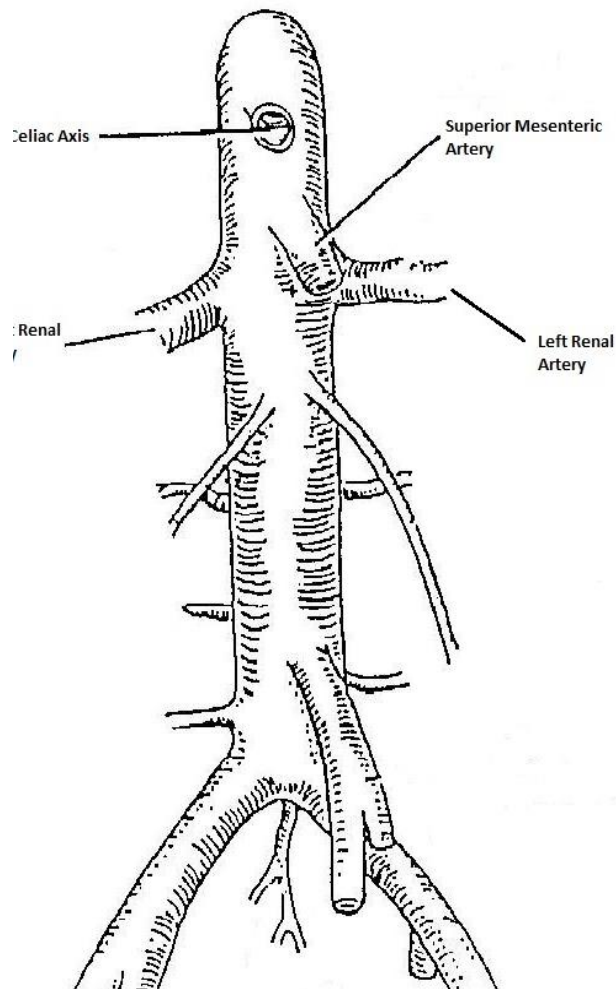
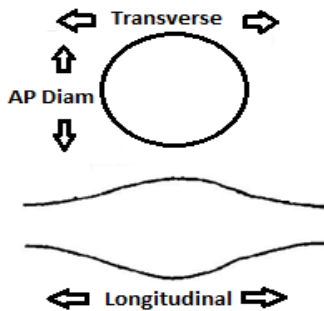
CARDIORISK AAA SCREENING

Patient Name: Lambrecht, Linda Date: 6/10/2020

DOB: 11/25/1947 Sex: F

Referring Provider: Robert Leff, MD

Vascular Technician: Sandra Kuljis



Aorta Prox

1.9 cm Trans X 1.8 cm AP

Aorta Mid

1.7 cm Trans X 1.6 cm AP

Aorta Distal

1.3 cm Trans X 1.4 cm AP

Comments: No Abdominal Aortic Aneurysm was identified in the submitted images. There was a small amount of calcified plaque identified in the Abdominal Aorta.



