CardioRisk Laboratories

At the Heart of Good Health

♥ DETECT
♥ ASSESS
♥ PREVENT

CARDIORISK AAA SCREENING

Patient Name: Cross, Gayle Date: 6/10/2020

DOB: 5/11/1935 Sex: F

Referring Provider: Robert Leff, MD

Vascular Technician: Sandra Kuljis

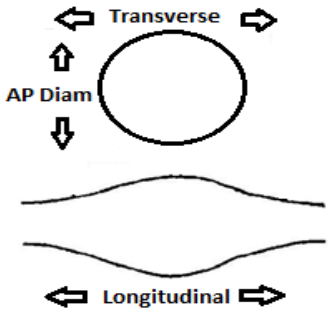

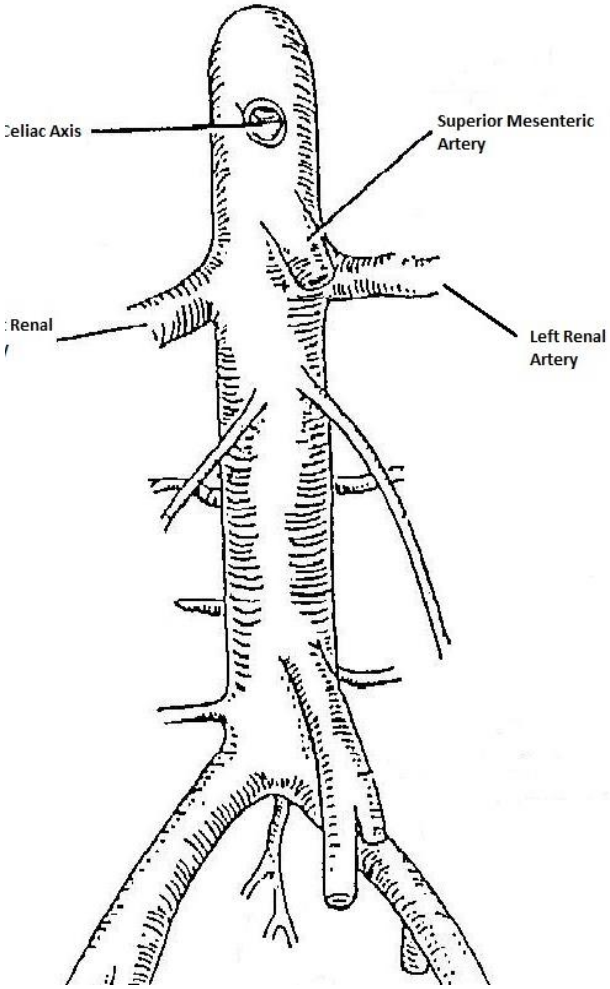

Aorta Prox

2.3 cm Trans X 2.5 cm AP

Aorta Mid

1.4 cm Trans X 1.4 cm AP

Aorta Distal

1.3 cm Trans X 1.3 cm AP

Comments: No Abdominal Aortic Aneurysm was identified in the submitted images. There was a small amount of calcified plaque identified in the Abdominal Aorta.

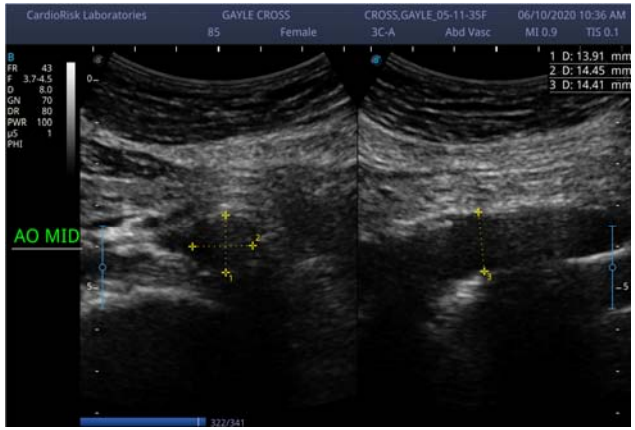
CardioRisk Laboratories
GAYLE CROSS
85
Female
CROSS,GAYLE_05-11-35F
3C-A
Abd Vasc
06/10/2020 10:36 AM
MI 0.9
TIS 0.1
1 D: 13.91 mm
2 D: 14.45 mm
3 D: 14.41 mm
AO MID

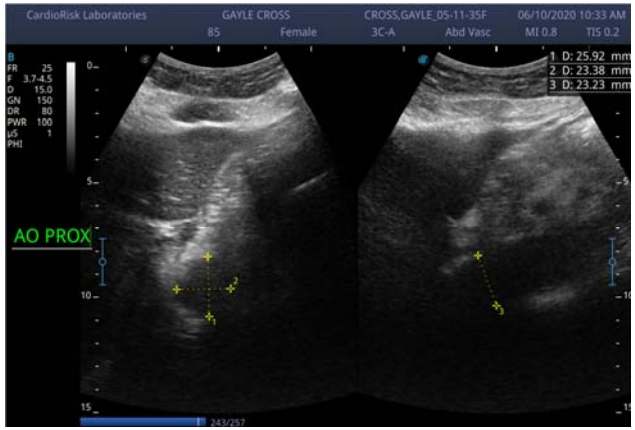
CardioRisk Laboratories
GAYLE CROSS
85
Female
CROSS,GAYLE_05-11-35F
3C-A
Abd Vasc
06/10/2020 10:33 AM
MI 0.8
TIS 0.2
1 D: 25.92 mm
2 D: 23.38 mm
3 D: 23.23 mm
AO PROX

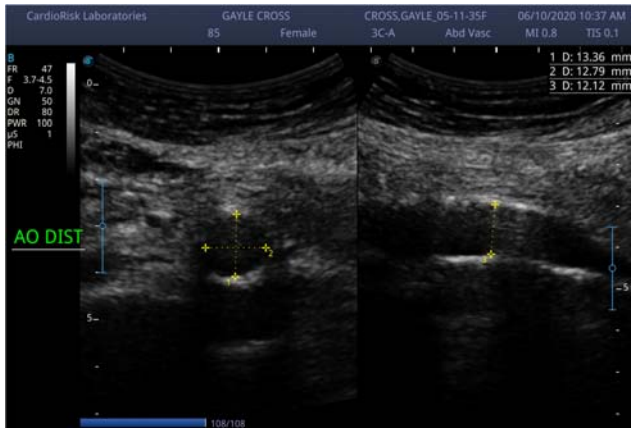
CardioRisk Laboratories
GAYLE CROSS
85
Female
CROSS,GAYLE_05-11-35F
3C-A
Abd Vasc
06/10/2020 10:37 AM
MI 0.8
TIS 0.1
1 D: 13.36 mm
2 D: 12.79 mm
3 D: 12.12 mm
AO DIST